

CLINICAL EVALUATION OF MELLADERM® PLUS: A HONEY-BASED WOUND GEL

KEY WORDS

Wound healing
Honey gel
Venous ulcers
Diabetes wounds
Debridement

The effects of honey are well documented as far as its antibacterial activity is concerned (Ceyhan and Ugur, 2001; Cooper et al, 2001; Alcaraz and Kelly, 2002). In this study, a total of 147 photo-documented case reports were examined to determine the effects of Melladerm® Plus (SanoMed Manufacturing). Nurses and doctors from both Belgium and the UK regularly submitted cases. A computer wound registration programme was used to collect all data in a standardised way. Depending on the underlying pathology, the wounds healed with a mean healing time of 46 days. The small amount of cases per pathology and the variability within the different pathologies made it very difficult to evaluate the results in a clear and comprehensive way. A comparison with a similar photo-documented, standardised database that used different dressings, showed that the healing time with honey gel was 26% faster than with other high-tech dressings. This result is probably due to the quick debriding and antibacterial activity of the gel, with the best results seen in infected ulcers. The main conclusion of this study is that the new honey gel is at least as good as other available high-tech dressings.

References

Alcaraz A, Kelly J (2002) Treatment of an infected venous leg ulcer with honey dressings. *Br J Nurs* Jul 11–24(13): 859–66

Baghel PS, Shukla S, Mathur RK, Randa R (2009) A comparative study to evaluate the effect of honey dressing and silver sulfadiazene dressing on wound healing in burn patients. *Indian J Plast Surg* Jul 42(2): 176–81

Ceyhan N, Ugur A (2001) Investigation of in vitro antimicrobial activity of honey. *Riv Biologia* May–Aug 94(2): 363–71

DOUG NESTJONES

Consultant specialist in woundcare,
University of Reading

JAN VANDEPUTTE

Wound care expert, RENVA bvba,
Belgium

Laboratory evidence suggests that honey has antibacterial properties that are due partly to its acidity and partly to phytochemicals from the nectar of particular plants (Molan, 2004). More recent research, however, shows that the phytochemicals do not play such a major role, as discussed later in this article (Nisbet et al, 2010). Honey can remove *Enterococcus* species and *Pseudomonas aeruginosa* from multiple, infected, non-healing leg ulcers caused by meningococcal

septicaemia (Dunford et al, 2000), with simultaneous loss of malodour, as well as a reduction in pain.

The most noticeable effect of using honey on a wound is the rapid formation of granulation tissue, which marks the transition from chronic inflammation to wound repair, followed by the clearance of infection (Efem, 1988; Hejase et al, 1996; Baghel et al, 2009). (For a complete overview of the benefits of honey in wound care, the authors refer to Molan [2002]).

It is clear that honey can be considered as nature's high-tech dressing, but honey itself is not user-friendly. Nor is the use of honey in wound care a new phenomenon — the ancient Egyptians mixed honey with fat and other ingredients (Jones, 2001).

Honey does not always kill fungi to the same extent as it kills bacteria (Willix et al, 1992), and the concentration of honey needed to kill *Candida albicans* is usually 100%, whereas most bacteria are killed at concentrations of 20% and even 10%. The main reason for honey's antibacterial qualities is its osmotic effect (high concentration of molecules) and the presence of glucose, which produces hydrogen peroxide in small amounts, but enough to kill microorganisms.

Schmidt et al (1993) have demonstrated that hydrogen peroxide (H_2O_2) stimulates fibroblast growth in cell culture at micro- and nanomolar concentrations. The hydrogen peroxide production of any wound technology is, in the authors' experience quite important, but is often clouded by other factors, such as the honey source.

Nisbet et al (2010), evaluated three different types of honey to check the phytochemical effect on the healing of full-thickness wounds in rabbits. Their aim was to see a difference associated with the flower source of the honeys. They wrongly assumed that, currently, only two (Medihoney® [Derma Sciences] and Manuka honey) are approved for use in wounds (this is not the case and many honeys are actually approved by CE legislation to be used in wounds), and therefore, they expected to see a difference in healing between the different honeys.

More specifically, Nisbet et al (2010) wanted to discover whether unifloral honey was better than multifloral honey, as had been suggested in some publications, such as Subrahmanyam et al (2001). Nisbet et al (2010), could find no statistical difference between the honeys. This is consistent with the authors' experience, that the origin of the honey used in a wound care preparation is not the major factor in obtaining a functional product. The key, then, is how the honey is treated during the production/sterilisation process.

In some commercially available gels, certain ingredients can create allergies or can destroy the benefits of the honey. For instance, when honey is heated above 40°C, glucose oxidase will be destroyed and will fail to produce H_2O_2 when in contact with water/wound fluid. When honey hydrogels (mixture of honey and monomers) are manufactured, they are heavily diluted with water, and irradiated to achieve maximum cross-linking, which destroys all of the benefits of the honey. Some honeys, such as Manuka honey, do not generate H_2O_2 as they naturally contain vitamin C, which destroys the H_2O_2 as soon as it is produced.

In some commercially available honey gels, vitamin C is an ingredient (displayed on the product packaging), which implies that these gels do not produce H_2O_2 at all. It is also important to check the pH of the honey gels to evaluate whether the pH is still in the range of 3.2–4.5. As explained later in this article, the pH level of the product used on wounds with a low pH (3–5) can have a very positive effect on the healing (Melladerm Plus has a pH level of 4.3).

Honey has a pH of between 3.2 to 4.5, but when mixed with other components, the end product can have a pH of 7 and above, thus losing the benefits of acidity. In other words, it is very difficult for a clinician to evaluate the difference of the commercially available honey products because most companies tend to advertise the honey source and the benefits that this brings, but fail to explain the consequences of the production process used to manufacture/sterilise the end product.

A new honey-based gel, Melladerm Plus, was developed by SanoMed Manufacturing. Melladerm Plus consists of honey, PEG 4000, propylene glycol and glycerine. This gel is patented (Europe and USA), CE marked and has been on the market for around four years. In this article, the authors will elaborate on some tests involving this product and the clinical outcomes.

ZONE OF INHIBITION TEST

To evaluate the long-term effects of H_2O_2 production, a zone of inhibition test was performed, showing that honey gel could be diluted 30 times before losing its antibacterial activity against *Staphylococcus aureus*. To execute the

'The most noticeable effect of using honey on a wound is the rapid formation of granulation tissue'

References

- Cooper RA, Molan PC, Harding KG (1999) Antibacterial activity of honey against strains of *Staphylococcus aureus* isolated from infected wounds. *J R Soc Med* 92: 283–85
- Cooper RA, Molan PC (1999) The use of honey as an antiseptic in managing pseudomonas infection. *J Wound Care* 8: 161–64
- Cooper RA, Wigley P, Burton NF (2000) Susceptibility of multiresistant strains of *Burkholderia cepacia* to honey. *Lett Appl Microbiol* 31: 20–24
- Cooper RA, Molan PC, Harding KG (2002) The sensitivity to honey of gram-positive cocci of clinical significance isolated from wounds. *J Appl Microbiol* 93: 857–63
- Dunford C, Cooper RA, Molan PC, White R (2000) The use of honey in wound management. *Nurs Times* (NT plus) 96(14): 7–9

'Oxyhemoglobin releases its oxygen more readily in an acidic environment'

References

Efem SE (1988) Clinical observations on the wound healing properties of honey. *Br J Surg* 75: 679–81

Hejase MJ, Simonin JE, Bihrl R, Coogan CL (1996) Genital Fournier's gangrene: experience with 38 patients. *Urology* 47(5): 734–39

Jones HR (2001) Honey and healing through the ages. In Munn, PA (ed) *Honey and healing*. IBRA; Cardiff, 1–4

Karayil S, Deshpande SD, Koppikar G (1998) Effect of honey on multidrug resistant organisms and its synergistic action with three common antibiotics. *VJ Postgrad Med* Oct–Dec 44(4): 93–6.

Kaufman T, Eichenlaub EH, Agel MF, Levin M, Futrell JW (1985) Topical acidification promotes healing of experimental deep partial thickness skin burns: a randomized double blind preliminary study. *Burns* 12(2): 84–90

Leveen H, Falk G, Borek B et al (1973) Chemical acidification of wounds. *Ann Surg* Dec: 745–53

Molan PC (1999) Why honey is effective as a medicine. Part 1. The nature of the antibacterial activity. *Bee World* 73(1): 5–28

actual assay, the authors chose an LMG-reference culture, i.e. *S. aureus subsp. aureus*. The test strain is cultivated in triple sugar broth (TBS) and then incubated at 35°C for 24 hours. By means of pour plate method, the concentration of the overnight culture is determined (1x10⁹ cfu/ml).

A 1,000-fold dilution of this overnight culture in sterile physiological water provides a homogeneous suspension with a concentration of 1x10⁶ cfu/ml. Then 1.0ml of this suspension is added to 100ml of an appropriate medium (Colombia-agar +5% sheep blood) and gives an end concentration of 1x10⁴ cfu/ml. The inoculated medium is now ready to be poured into glass petri-dishes (19cm in diameter, per 100ml).

When the medium is solid, the authors pierced five holes (Ø — 13.8mm) on each plate. A serial dilution of the honey gel was prepared in sterile distilled water. A 20% (m/v%) stock solution of the gel was prepared in sterile distilled water. Starting from this solution, the following dilutions were made — 20% down to 1% m/v, with every whole percentage in between. From each dilution, 200µl is transferred into the prepared wells in the plates. As mentioned before, at five dilutions per plate.

Due to the β-haemolytic activity (haemolytic activity leads to a colour forming in the agar gel and allows an easy

detection of where the bacteria are) of the used strand of *S. aureus*, it is relatively easy to detect the inhibition zones (the darker, brownish circles around the pierced wells, (see *Figures 1* and *2*).

The authors concluded that Melladerm Plus inhibits the growth of *S. aureus* when the concentration of the product is higher than 4% mass/volume (m/v).

This clearly demonstrates the effect of the H²O² activity of the honey. Honey or honey-based products that fail to produce H²O² must have another mechanism to achieve the same antibacterial effect when diluted.

ACIDIFICATION OF WOUNDS — THE ROLE OF HONEY

In 1973, Leveen et al published an article showing that when the release of oxygen from oxyhemoglobin is impeded, oxygen transport to the tissues is impaired sufficiently to interfere with wound healing and also to cause tissue necrosis.

Oxyhemoglobin releases its oxygen more readily in an acidic environment. As ascertained by the Bohr effect, when there are excess protons in the solution (blood), the state of deoxyhemoglobin is more likely to exist than oxyhemoglobin. Even small changes in pH could induce wide changes in the standard oxygen dissociation curve (Naeraa et al, 1963).

Leveen et al (1973) tested 137 wounds and found that 89.9% had a pH of 7.4–9. The higher the pH, the longer it took to heal the wounds. Leveen demonstrated that a five-fold increase of oxygen released from the oxyhemoglobin was obtained by a shift of only 0.9 pH units. Any factor that causes even a small change in the pH of the healing wound might appreciably alter the available supply of oxygen to the tissue. Conversely, even mild acidification of a wound might substantially hasten healing by enriching the supply of oxygen to the tissues (Kaufman et al, 1985).

The authors believe that using a gel containing high molecular weight water soluble particles, such as PEG 4000, with a low pH can change the local pH in a wound — resulting in a significantly higher oxygen perfusion in the wound. The pH



Figure 1 (above) shows dilutions 11% to 15% m/v, while Figure 2 (below) shows dilutions 1% to 5% m/v.



of Melladerm Plus is 5. Faster healing was seen when using Melladerm Plus in acute and chronic wounds.

More research should reveal if this is due to the acidification of the wound. A low pH will also stop proteases from working in the wound. Most metalloproteases are active (dissolving proteins) in a pH range of 7–9. Lowering the pH will stop the proteases from breaking down the wound tissue.

METHOD

Some 147 patients with chronic wounds were treated with the test dressing until complete wound closure was achieved. The clinical data were obtained in accordance with Medical Device Directive (MDD), annex X and harmonised standard ISO 14155. Community nurses treated the majority of the patients at home, while the rest were treated at hospital or in a care home setting. Where possible, photographs were dated and a label was placed next to the wound. None of the nurses were paid or compensated for taking part in the study and a computer programme was used to collect the data in a standardised way. The size of the ulcers and the degree of pathology was important in order to effectively interpret the healing time.

Next to healing time, other parameters were also taken into account. The honey gel was found to be very user-friendly and usually the nurse applied the gel on to gauze or a non-adherent dressing (Melolin[®], Smith & Nephew). Most nurses reported that a thin layer of gel applied once a day gave better results than large amounts of gel. Honey-based products are often known for a stinging effect during the first hours and the authors discovered that in the study group, complaints about a pain sensation almost always related to

patients with arterial insufficiency.

In the other pathology group, complaints about pain were not often reported. In some cases, a red inflammatory ring around the wound was evident, especially in wounds with lots of necrotic tissue, which is quickly dissolved by the honey gel. The authors believe that this is due to the acidic environment bringing more blood into the wound area

Performance compared with other dressings

In order to get some kind of perspective, the authors looked at older data (from 1998–2002), as well as other photo-documented case reports that used high-tech dressings. They also used an existing database of 74 patients (nine skin tears, 18 burns, 24 venous ulcers and 22 pressure ulcers) to compare the healing rates with the honey gel (see *Table 1* for a comparison of healing times). The dressings employed in the study were all moist healing and were all considered high-tech dressings. Examples include: DuoDerm[®] (ConvaTec), Comfeel[®] (Coloplast), Kaltostat[®] (ConvaTec), OpSite[®] (Smith & Nephew), Intra Site Gel[®] (Smith & Nephew), Alevyn[®] (Smith & Nephew), Elasto-Gel[®] (Southwest Technologies), Betadine[®] (Purdue Products) and Flammazine[®] (Sinclair IS Pharma).

The healing time and all other relevant parameters were also collected. The overall difference in healing time was in favour of the honey gel, with an average of 26% faster healing for all wound types.

ANALYSIS PER WOUND TYPE

Burns results

In the comparison group (those patients from the older database), there were 12 burn wounds, mainly treated with

Table 1
Mean healing time comparison

	Healing time with other products (days)	Healing time with Melladerm Plus	% difference +P value *Statistically significant
Skin tears	24	17	24% ($p = 0.490$)
Burns	22	16	27% ($p = 0.045$)*
Venous ulcers	62	38	39% ($p = 0.001$)*
Pressure ulcers	93	78	17% ($p = 0.027$)
Diabetes	48	37	23% ($p = 0.260$)

‘The dressings employed in the study were all moist healing and were all considered high-tech dressings’

References

- Molan PC (1999) The role of honey in the management of wounds. *J Wound Care* 8(8): 415–18
- Molan PC (2002) Re-introducing honey in the management of wounds and ulcers – Theory and Practice, *Ostomy Wound Manage*, November 48: 28–40
- Molan PC (2004) The role of honey in the management of wounds. *J Wound Care* 13(9): 353–56
- Naeraa N, Peterson ES Boye E (1963) The influence of simultaneous independent Changes in pH and Carbon Dioxide Tension in the In Vitro Oxygen Tension Saturation Relationships in Human Blood. *Scand J Clin Lab Invest* 15(141)

'The average healing time for the honey gel-treated burns was 16 days and in the other group it was 22 days'

Flamazine and Betadine. In the test dressing group, there were also 12 burns. Most of the burns were first or superficial second-degree burns (which will heal without surgical debridement in 21 days), and in both groups, there were two patients with deep second-degree burns. In two cases, the authors could compare treatments for just one patient (they had two arms burned). In these two cases the authors could see a 30% difference in healing time in favour of the honey gel treatment.

The average healing time for the honey gel-treated burns was 16 days and in the other group it was 22 days. The average healing time difference was, therefore, 27% faster for the honey gel group.

In both groups, the age range of the patients encompassed infants through to older people. The average size of the burns was 52cm² for the honey gel group and 51cm² for the comparison group.

The difference in healing time was statistically (unpaired t-test) significant (the two-tailed P value = 0.0451). The difference in healing time might be explained by the antibacterial activity of the honey gel and the quick debridement of dead tissue and slough.

Skin tears

In the comparison group, there were 13 patients with skin tears, compared with 17 in the honey gel group, but four patients were referred to the venous ulcer group, since this was the dominant underlying pathology. There was a variety of lesions from superficial flaps to deeper wounds.

The average size of the skin tears was 18cm² in the honey gel group and 16.2cm² in the comparison group. The average healing time — 18 days versus 24 days for honey gel group and comparison group respectively — was not statistically significant (the two-tailed P value equals 0.4965). The difference in healing time was 24% faster for the honey gel group.

In the cases where the flaps stayed intact there was no difference in healing time. In the instances where the flap became necrotic, quicker debridement made the critical difference in terms of healing time. Where there was no necrotic tissue present in the wound, there was hardly any difference in healing time between the products.

Diabetes

In the comparison group there were 14 patients with similar types of wounds and demographic data. The main treatment was Betadine gel for this group and the average age of the patients was 64. A Wagner classification was applied and most ulcers were class II, with three patients class III. The average size of the diabetes wounds was 5.4cm² in the honey gel group and 5.8cm² in the comparison group. The average healing time was found to be 37 and 48 days in the honey gel and comparison group, respectively.

The difference was not statistically significant (the two-tailed P value = 0.2605). The difference in healing time was mainly attributed to a better debridement and a more controlled bioburden pattern in the honey gel group, while the comparison group treated with Betadine suffered from a lack of adequate debridement leading to a delay in healing.

Venous ulcer

There were a total of 50 patients falling within this category and treated with the test dressing. The average age was 76. Meanwhile, there were 24 patients in the comparison group. The average healing time for the honey gel group was 38 days (the range being five to 90 days, with a median of 34), whereas the comparison group's average healing time was 62 days. This equated to a healing time difference of 39%, which was statistically significant (the two-tailed P value = 0.0011). The average ulcer size in the honey gel group was 21.5cm², while in the comparison group it was 18cm².

The first striking fact was that the healing time of the venous ulcers was very diverse and not related to the ulcer size. In some cases, rather large, superficial ulcers (for example, 20cm²) healed in 20 days, while several ulcers with a size of between 1cm² to 3cm² required 90 days to complete healing.

It was discovered that a key factor is the degree of venous insufficiency and whether the patient is receiving the correct compression therapy. In four cases where different products were used for months without healing taking place, the wound was found to heal completely with the honey gel. Some ulcers (for instance, small ones on top of the inner ankle bone) needed considerably more time

References

Nisbet HO, Nisbet C, Yarim M, Guler A, Ozak A (2010) Effects of Three Types of Honey on Cutaneous Wound Healing *Wounds* 22(11): 275–83

Schmidt RJ, Chung LY, Andrews AM et al (1993) Hydrogen peroxide is a murine (L929) fibroblast cell proliferant at micro- to nanomolar concentrations. In: Harding KG, Cherry G, Dealey C, Turner TD, eds. *Proceedings of the Second European Conference on Advances in Wound Management* London: October 20–23

Subrahmanyam M, Sahapure AG, Nagane NS, Bhagwat VR, Ganu JV (2001) Effects of topical application of honey on burn wound healing. *Annals of Burns and Fire Disasters*. 14(3)

Willix DJ, Molan PC, Harfoot CG (1992) A comparison of the sensitivity of wound infecting species of bacteria to the antibacterial activity of manuka honey and other honey. *J Appl Bacteriol* 73: 388–94

to heat and were usually not affected by the compression therapy. Ulcers that had sufficient compression therapy healed faster — unfortunately, most patients did not receive the correct compression therapy at home. In a sizeable amount of cases, the compliance of the patient was found to be the biggest obstacle to overcome.

Pressure ulcers

The number of patients in the honey gel test dressing group was 15, with an average age of 81.7, while in the comparison group, there were 22 patients. The extent of the ulcers varied, but in most of the cases, the patients were bedridden. The mean ulcer size was 41.6cm² in the honey gel group and 56cm² in the comparison group. The honey gel removed large amounts of necrotic tissue and due to the osmotic power of the honey granulation tissue is growing quickly.

The average healing time was 78 days for the honey gel group and 93 days for the comparison group (the two-tailed P value equalled 0.2737) and was not statistically significant; equating to an average healing time difference of 17%. The larger pressure ulcers that used to be seen in the 1990s are rarely seen now, due mainly to improved mattresses and better nursing care.

Infected ulcers

In terms of infected ulcers, there was no comparison group to compare with, but the test dressing group comprised 25 patients. The average size of the ulcers was 7.98cm², while the average healing time with the honey gel was 18 days. In those cases, the better healing rate was seen.

Looking at the origin of the infected wounds the authors mainly found

surgical wounds that discharged pus for a couple of days postoperatively.

In some cases, the patient was in a physically bad condition, but there were also younger, healthy patients who required surgery after road accidents. Again all the wounds did heal and the infection cleared very quickly after the application of the honey gel. The results with honey gel for the treatment of infected ulcers are very promising and can be explained by its antimicrobial activity.

DISCUSSION

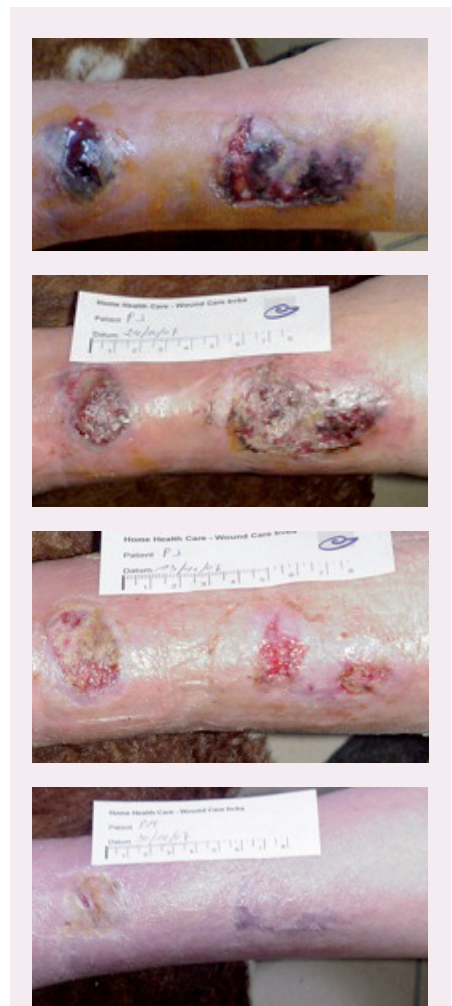To get an overview of the entire database, all of the pictures from the case reports were placed on a large table for our perusal. Various statistical tests were then performed, and 147 fully documented cases proved to be enough to draw a clear scientific conclusion.

The main positives of using honey gel are the quick debridement of necrotic tissue, its antibacterial properties and the acidification of the wound environment, which releases more oxygen into the tissue. It is clear that the honey gel has benefits in the treatment of infected wounds and in wounds with large amounts of necrotic tissue. The authors will continue to build-up the wound database in the same standardised way.

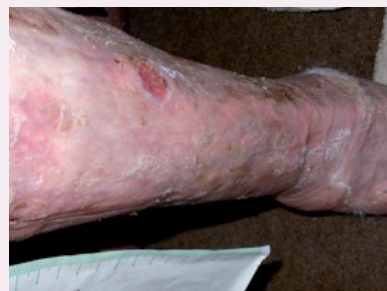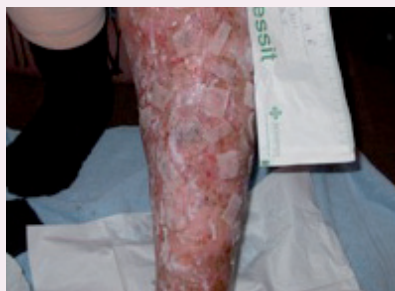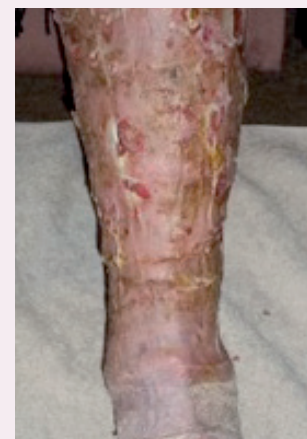CASE STUDIES

Case study 1

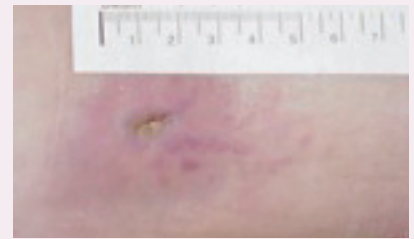
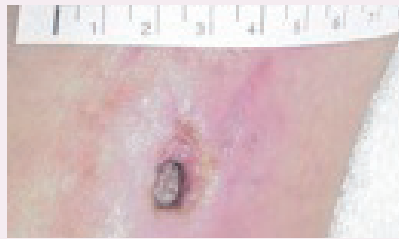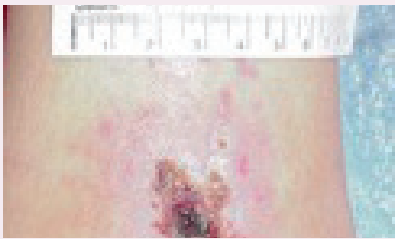A 69-year-old female with a skin tear presented with an ulcer that was 34cm² (Figures 3–6). She had previously been treated with Betadine and was not receiving any compression therapy. The new treatment plan involved applying



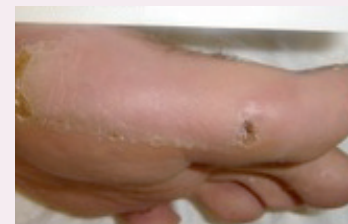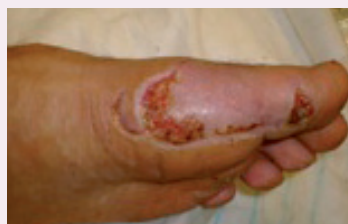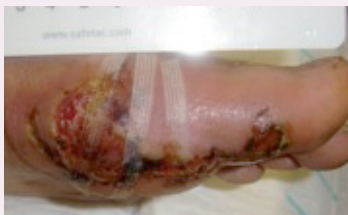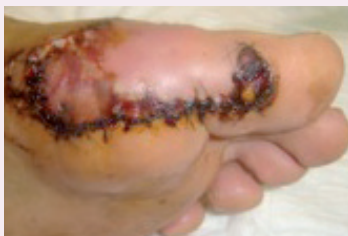Figures 3-6 (above from top) relate to case study 1: 1) wound before Melladerm Plus was applied. Wound had been treated with Betadine gel. 2) Wound after three days' honey gel treatment. 3) Wound after 20 days' honey gel treatment. Wound is debrided, while granulation and epithelialisation is commencing. 4) After 40 days, the wound is completely healed.



Figures 7-9 (above left to right) relate to case study 2: Figures 5 and 6 both show the wound after seven days of honey gel treatment — most of the crust has dissolved. Figure 7 shows the wound after 15 days of honey gel treatment and compression therapy.



Figures 10-12 (above left to right) relate to case study 3. From left to right, figure 10 is the wound on the day honey gel was first administered, figure 11 shows the wound cleaned, some nine days later, and figure 12 shows the wound almost healed, 20 days after treatment.



Figures 13-16 (top down) relate to case study 4. Figure 13 shows the wound on 12/09/2009, when treatment with Melladerm Plus commenced. Figure 14 relates to the wound on 17/09/2009, while figure 15 shows the toe on 21/09/2009. Figure 16 shows the healed wound.

Melladerm Plus, while cleansing involved SanoSkin® Cleanser (SanoMed Manufacturing).

Case study 2

A 76-year-old female developed a venous ulcer on her left leg, but due to excess

amounts of exudate, the whole leg became one large wound over a period of 18 months (Figures 7–9). Prior to honey gel treatment, the leg was treated by being washed in water twice a week — emollient and compression bandaging were then applied. The honey gel treatment comprised 10 minutes of rubbing over the entire wound area. Over 80% of the necrotic tissue was removed at this point with gentle pressure from the handle of disposable forceps. The remaining crust dissolved over the next few days.

Case study 3

This case involves a 70-year-old female with venous insufficiency and an ulcer of 1cm² (Figures 10–12). She had been treated for six months with Betadine gel, while compression therapy took place both before and after the honey gel treatment. Honey gel was prescribed by the vascular surgeon and the wound was fully healed after 51 days.

Case study 4

The patient was a 30-year-old male with an infected (surgical) trauma wound (Figures 13–16). The ulcer size was 12cm² and before honey-based gel the wound had been treated with Betadine. The revised treatment plan involved Melladerm Plus Tulle, as well as cleansing with SanoSkin Cleanser.

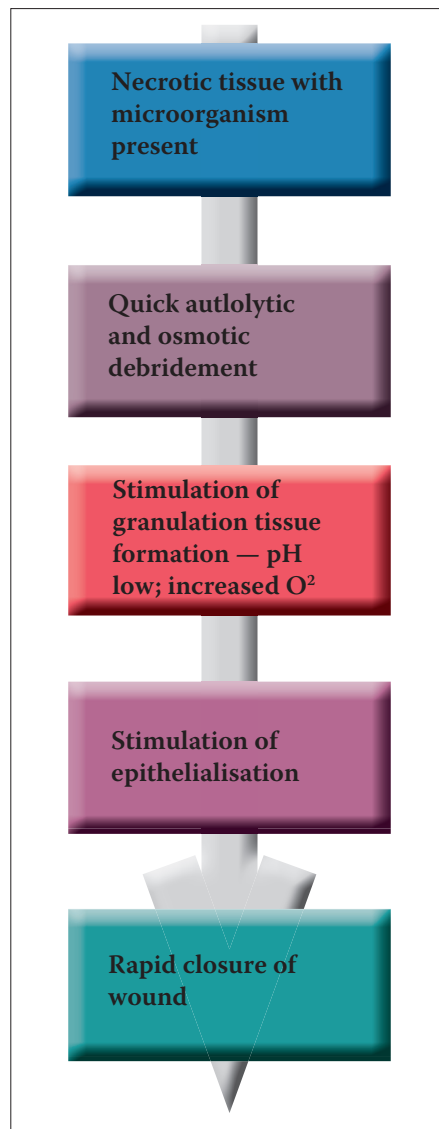


Figure 17: Flow diagram explaining the stages of a honey-based gel's action.

CONCLUSION

The honey-based gel used here appears to perform at least on a par with other high tech dressings. The clinical results are consistent with the reports of the effect of honey in wound care in other studies. Further research is, however, needed to determine the effect of the acidification of the wound and the differences in the honey products that are currently available. **WUK**